

## Use of Fenestrations in Acellular Dermal Allograft in Two-Stage Tissue Expander/Implant Breast Reconstruction

Jenna B. Martin, M.D.

Ryan Moore, B.S.

Keyianoosh Z. Paydar, M.D.

Garrett A. Wirth, M.D., M.S.

Orange, Calif.



**Summary:** The authors present a new technique of alteration of the acellular dermal matrix through strategically placed fenestrations, improving the reconstructive experience and overall cosmetic outcome. The authors present a retrospective chart review following two surgeons' experience at the University of California, Irvine, Department of Plastic Surgery using surgeon-designed fenestrated acellular dermal matrices in two-stage tissue expander breast reconstruction. The authors found that this leads to improved intraoperative fill volume, decreased number of postoperative expansions, increased expansion rate with subjectively less pain, decreased time to full expansion, and subjectively improved cosmetic outcome. (*Plast. Reconstr. Surg.* 134: 901, 2014.)

**CLINICAL QUESTION/LEVEL OF EVIDENCE:** Therapeutic, III.

In 2011, over 69,000 two-stage tissue expander and implant-based reconstructions were performed, accounting for 70 percent of breast reconstructions in the United States.<sup>1</sup> Acellular dermal matrix used as an inferolateral sling in two-stage breast reconstructions assists with creating the tissue expander pocket with well-described benefits.<sup>2-4</sup>

Although acellular dermal matrix-based reconstruction is not novel,<sup>2-9</sup> limited information exists regarding structural modifications to improve the reconstructive outcome. The authors report improvement in intraoperative tissue expander fill volume and percentage, number of postoperative expansions, and total fill volume using fenestrated acellular dermal matrix compared with nonfenestrated acellular dermal matrix tissue expander.

### PATIENTS AND METHODS

We conducted an institutional review board-approved, retrospective chart review of two-stage breast reconstruction using acellular dermal matrix at the University of California, Irvine. All women who underwent mastectomy and immediate breast reconstruction using tissue expander

with or without acellular dermal matrix from 2008 to 2012 (institutional review board no. 2012-8663) were included. The presence of fenestrations, tobacco use, comorbid conditions, preoperative or postoperative chemotherapy, radiation therapy, body mass index, type of allograft [AlloDerm (LifeCell Corp., Branchburg, N.J.), AlloMax (Bard, Inc., Warwick, R.I.), or FlexHD (Ethicon, Inc., Somerville, N.J.)], acellular dermal matrix size, drain placement, tissue expander size, and intraoperative fill volume, subsequent outpatient postoperative expansions (fill volumes), time to full expansion, drain removal, and dates of subsequent surgery were recorded. All patients were followed for a minimum of 1 year.

### Technique

Specifically spaced fenestrations were created in the allograft in a novel technique by the authors (Fig. 1, *left* and *center*). The superior edge of the allograft was sutured in an interrupted fashion to the pectoralis major muscle (after chest wall release), laterally to the serratus anterior fascia, and inferiorly to the inframammary fold. The allograft midline is marked for alignment with the breast meridian, leaving appropriate acellular dermal matrix pleats between sutures to account for immediate expansion. The expander is then placed in the partial submuscular/allograft pocket

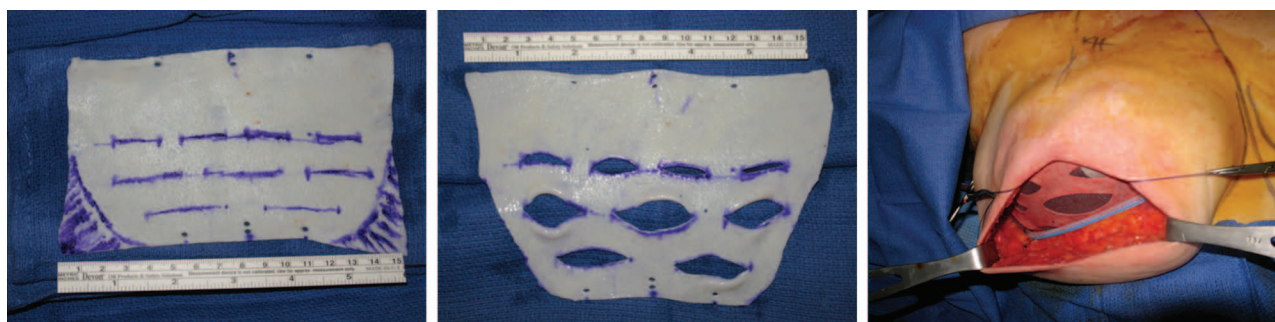*From the Department of Plastic Surgery, University of California, Irvine.*

*Received for publication December 21, 2013; accepted May 6, 2014.*

*Copyright © 2014 by the American Society of Plastic Surgeons*

DOI: 10.1097/PRS.0000000000000598

**Disclosure:** *The authors have no financial disclosures to report in relation to the content of this article.*



**Fig. 1.** Intraoperative images. (Left) An 8 × 16-cm piece of AlloDerm with planned fenestrations and trimming. (Center) Widely spaced fenestrations before AlloDerm placement. (Right) Tissue expander filled to greater than 50 percent with fenestrations between the subpectoralis and subcutaneous planes. A single drain is placed in the subcutaneous space.

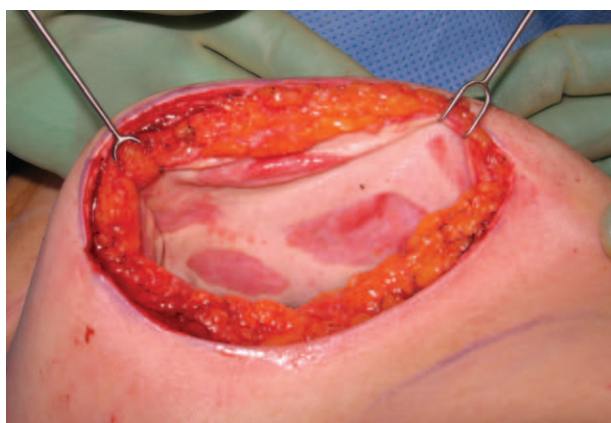and filled using a closed system without pectoralis muscle strain and with tension-free skin closure. A single 15-French round drain is placed in the subcutaneous plane (Fig. 1, right). Following complete tissue expansion, patients underwent implant exchange (Fig. 2), often with subsequent nipple reconstruction and tattooing (Fig. 3).

### Statistical Analysis

Tissue expander characteristics and fill dynamics of fenestrated versus nonfenestrated acellular dermal matrix groups were analyzed using the Wilcoxon rank sum test, as the groups were not normally distributed.

## RESULTS

The fenestrated and nonfenestrated acellular dermal matrix groups were unequal in size. Forty-two patients with two-stage reconstruction totaled 70 breasts. There were six nonfenestrated acellular dermal matrix patients (seven breasts) (five FlexHD and two AlloDerm) versus 63 fenestrated



**Fig. 2.** Incorporation of fenestrated allograft with mastectomy skin flaps at the time of implant exchange.

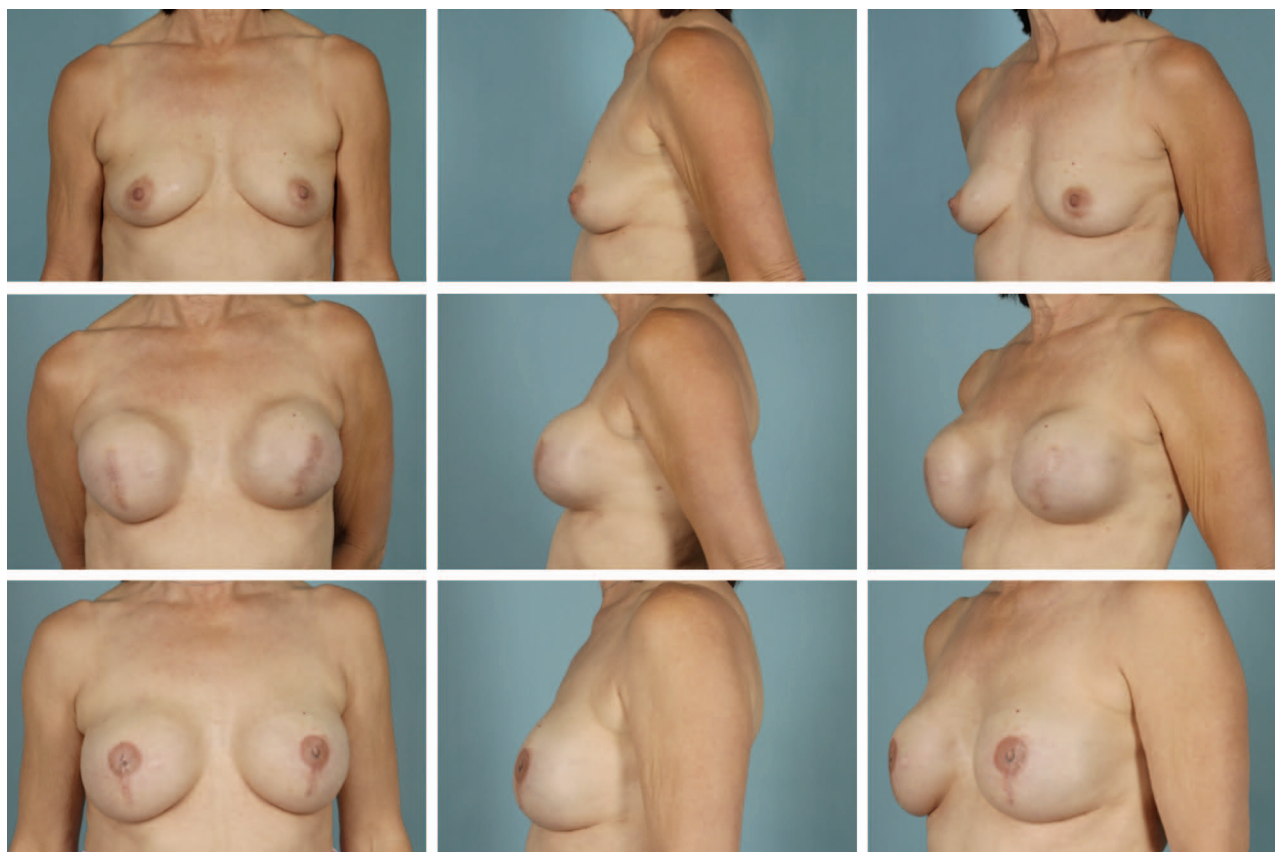
acellular dermal matrix patients (six FlexHD, 12 AlloMax, and 45 AlloDerm). Patient group demographics are listed in Table 1.

Differences in tissue expander characteristics and fill dynamics between the two groups were statistically significant: mean expander size, intraoperative fill volume, intraoperative fill percentage, number of postoperative expansions, total fill volume, and expansion rate (Table 1) varied between nonfenestrated versus fenestrated dermal matrix.

In addition, 30- and 90-day postoperative complication rates were compared for each of the three types of allograft used. Of the 45 fenestrated AlloDerm breast reconstructions, two patients required removal of the tissue expander within 30 days (4.4 percent), with no additional explanations through 90 days (4.4 percent total). One patient had a history of radiation therapy and was receiving chemotherapy at the time of explantation. Of the 12 fenestrated AlloMax breasts reconstructed, one tissue expander was removed by 30 days (8.3 percent) in a patient who was receiving chemotherapy. Two additional tissue expanders were removed within 90 days (25.0 percent total) (one patient had a significant history of tobacco use and one received radiation therapy). Of the six fenestrated FlexHD breasts reconstructed, there were no tissue expander removals within 30 days and one tissue expander removal within 90 days (16.7 percent total) in a patient who received radiation therapy. The total complication rate requiring tissue expander removal was three of 63 within 30 days (4.8 percent) and six of 63 breasts within 90 days, or a total complication rate of 9.5 percent.

## DISCUSSION

Commonly, acellular dermal matrix–based breast reconstruction uses an inferolateral sling



**Fig. 3.** Patient with right ductal carcinoma in situ who underwent prophylactic left mastectomy. (Above) Preoperative images. (Center) Following full tissue expansion with expanders in place. (Below) Following implant exchange and three-dimensional nipple tattoo.

**Table 1. Tissue Expander Statistics**

	Nonfenestrated Mean (SD)	Fenestrated Mean (SD)	<i>p</i> *
Age, yr	51.33 (14.8)	46.78 (10.49)	0.3229
BMI, kg/m <sup>2</sup>	21.52 (1.33)	26.17 (5.22)	0.0289†
Expander size, cc	407.14 (53.45)	546.59 (165.92)	0.0244†
Intraoperative fill, ml	117.14 (85.97)	291.21 (167.21)	0.0031†
Total fill, ml	399.29 (117.35)	570.27 (168.58)	0.0106†
No. of postoperative expansions	4.86 (0.69)	3.81 (1.52)	0.0384†
Expansion rate (ml/fill)	69.36 (22.25)	127.10 (58.27)	0.0033†
Office fill per expansion, ml	59.56 (18.08)	81.53 (80.25)	0.0608
Intraoperative fill/expander size	0.28 (0.18)	0.52 (0.22)	0.0071†
Total fill/expander size	0.98 (0.26)	1.08 (0.15)	0.2706
Intraoperative fill/total fill	0.27 (0.14)	0.46 (0.17)	0.0103†
Days with drain in place	13.86 (10.3)	13.97 (6.52)	0.8324
Days to full expansion	116 (1292.9)	89.5 (102.4)	0.1815
Implant size, cc	338.5 (4421.97)	526.8 (170.62)	0.0219†

BMI, body mass index.

\*Wilcoxon rank sum test.

†Statistically significant (*p* < 0.05).

to improve tissue expander positioning, optimizing the breast “footprint,” decreasing the need for muscle dissection (rectus or serratus), and resulting in a hypothesized decrease in postoperative pain.<sup>3-5</sup> We believe our strategically placed fenestrations in the acellular dermal matrix facilitates precise control over the tissue expander

pocket, maintains control of the inframammary fold, decreases pain, and improves lower pole projection.

It is our belief that breast cosmesis benefits from the acellular dermal matrix fenestrations designed by the senior authors (K.Z.P. and G.A.W.). There appears to be improved lower pole

expansion, projection, and shape, even during the expansion process with the fenestrated acellular dermal matrix. The statistically significant increase in intraoperative fill volume may lead to faster time to complete fill. A single subcutaneous drain is used with fenestrated acellular dermal matrix compared with the two (one subcutaneous and one suballograft) required by nonfenestrated acellular dermal matrix. In addition, we noted subjectively less discomfort with the in-office expander fills. Although the fill volume per in-office expansion and time until implant exchange were not statistically significant in our study, we noted increased volume fill per office event and a shorter time to implant exchange. Anecdotally, our implant exchanges were easier and faster, and required fewer pocket revisions.

At the implant exchange, there was full integration of the fenestrated acellular dermal matrix with native tissue (Fig. 2). We believe the fenestrations improve effacement of the allograft with the mastectomy skin flaps, enhancing subsequent allograft integration.

The use of three different acellular dermal matrix products is a weakness of the study, although no group has found a statistically significant difference in complication rates.<sup>2</sup> We addressed this weakness by evaluating our postoperative complication rate for each allograft material, which was within the reported rate. Another limitation is inherent in the retrospective nature of the study and the lack of control subjects. Flap thickness and flap vascular insult varied between the three breast surgeons performing the mastectomies.

## CONCLUSIONS

In our experience, fenestrated acellular dermal matrix used in two-stage breast reconstruction leads to improved intraoperative fill volume,

decreased number of postoperative expansions, and enhanced expansion rate, with subjectively less pain and time to full expansion. In addition, patients experience an improved cosmetic outcome, definition of the breast footprint, and improved comfort resulting from the decreased number of in-office fill events.

**Jenna B. Martin, M.D.**

Department of Plastic Surgery  
University of California, Irvine  
200 South Manchester Avenue, Suite 650  
Orange, Calif. 92868  
jennabm@hs.uci.edu

## REFERENCES

1. Baxter RA. Acellular dermal matrices in breast surgery: Defining the problem and proof of concept. *Clin Plast Surg.* 2012;39:103–112.
2. Brooke S, Mesa M, Uluer M, et al. Complications in tissue expander breast reconstruction: A comparison of AlloDerm, DermaMatrix, and Flex HD acellular inferior pole dermal slings. *Ann Plast Surg.* 2012;69:347–349.
3. Spear S, Sher SR, Al-Attar A. Focus on techniques: Supporting the soft-tissue envelope in breast reconstruction. *Plast Reconstr Surg.* 2012;130(Suppl 2):89S–94S.
4. Nahabedian MY. Acellular dermal matrices in primary breast reconstruction: Principles, concepts, and indications. *Plast Reconstr Surg.* 2012;130(Suppl 2):44S–53S.
5. McCarthy CM, Lee CN, Halvorson EG, et al. The use of acellular dermal matrices in two-stage expander/implant reconstruction: A multicenter, blinded, randomized controlled trial. *Plast Reconstr Surg.* 2012;130(Suppl 2):57S–66S.
6. Kim JY, Davila AA, Persing S, et al. A meta-analysis of human acellular dermis and submuscular tissue expander breast reconstruction. *Plast Reconstr Surg.* 2012;129:28–41.
7. Nahabedian MY. AlloDerm performance in the setting of prosthetic breast surgery, infection, and irradiation. *Plast Reconstr Surg.* 2009;124:1743–1753.
8. Namnoum JD. Expander/implant reconstruction with AlloDerm: Recent experience. *Plast Reconstr Surg.* 2009;124:387–394.
9. Chun YS, Verma K, Rosen H, et al. Implant-based breast reconstruction using acellular dermal matrix and the risk of postoperative complications. *Plast Reconstr Surg.* 2010;125:429–436.